



PATIENT

Lucky Martinez-Bauer

PRESENTING CLINICAL SIGNS

History: Recheck echo.
-Pertinent previous echo findings (8/2021 MML): Mild MR, no LA or LVE. LA: 1.8, LV: 3.7.

SPECIES

Canine

ELECTROCARDIOGRAPHIC FINDINGS *Note: Single lead ECGs are evaluated as a rhythm strip.

Morphology/MEA cannot be definitively commented on.
A single lead ECG is available; 50mm/s, 20mm/mV. The average heart rate is 100bpm (range 75-130bpm). The rhythm is sinus in origin, with a p for every QRS complex and vice versa. The P and QRS morphologies are positive. No ectopic beats, pauses or other dysrhythmias observed.
ECG diagnosis: Normal sinus rhythm with respiratory variation.

BREED

Min. Schnauzer Mix

SEX

Male Intact

AGE

8 years

ECHOCARDIOGRAM FINDINGS

2D, m-mode, color flow and doppler imaging is available. Diffuse thickening of mitral valve leaflets with mild prolapse into the left atrial lumen. Moderate eccentric mitral regurgitation with moderate left atrial dilation. Normal MR velocity. Mild LV dilation with hyperdynamic myocardial function. The tricuspid valve appears thickened with septal prolapse and mild tricuspid regurgitation. Normal velocity. Normal right atrial and ventricular diameter and morphology. The pulmonic and aortic valves are normal in morphology and mobility. Normal pulmonic and aortic outflow velocities with laminar flow. No obvious aortic or pulmonic insufficiency. No pericardial or pleural effusion noted. No obvious cardiac masses.

WEIGHT

24.9lbs

CARDIAC CHART

INTERPRETED BY

Maggie Machen Lamy,
DVM, DACVIM
(Cardiology)

CANINE CARDIAC PARAMETERS	MR VMAX (m/s)	TR VMAX (m/s)	LA/AO (Boon method)	LA/AO (Heart Base; Swe)	FS (%)	EF (%)	EPSS (cm)
NORMAL PARAMETER	4.5-5.5	<2.7	1.3	<1.6	28-40	40-100	<0.6
PATIENT	5.5	2.0	NM	1.8	47	90	NM
CANINE CARDIAC PARAMETERS	HR (BPM)	AV VMAX (m/s)	PV MAX (m/s)	BODY WEIGHT (kg)	LA 2D short axis Base view (cm)	LVIDd Avg; 2D and m-mode short axis (cm)	LVIDs Avg; 2D and m-mode short axis (cm)
NORMAL PARAMETER	50-100	0.7-1.7	0.7-1.6	BELOW	BELOW	BELOW	BELOW
PATIENT	NM	1.4	0.9	11.3	2.7	4.3	2.3
*Normal chamber parameters expressed as a mean value (SD)				3	1.27 (5.3)	2.46 (2.46)	1.36 (5.5)
BODY WEIGHT DEPENDENT PARAMETERS				5	1.40 (4.5)	2.74 (5.2)	1.60 (4.7)
<i>*Note: All measurements based upon multi-modal images and methods. An average value is reported.</i>				10	1.50 (3.8)	3.27 (3.5)	2.06 (3.1)
				15	1.83 (2.0)	3.71 (2.4)	2.43 (2.1)
				20	2.02 (1.9)	4.14 (2.2)	2.80 (2.0)
				25	2.18 (2.4)	4.48 (2.9)	3.10 (2.5)
				30	2.33 (3.3)	4.83 (3.9)	3.39 (3.4)
				35	2.48 (4.3)	5.17 (5.0)	3.69 (4.5)
				40	2.62 (5.2)	5.48 (6.1)	3.96 (5.4)
				50	2.88 (7.1)	6.07 (8.3)	4.46 (7.4)

Adapted from June Boon, Veterinary Echocardiography, 1998
Rishniw M and Hollis NE, J Vet Intern Med 2000; 14:429-435
Hansson et al, Vet Rad and Ultrasound 2002
Bonagura et al. Echocardiography: principles of interpretation, Vet Clin North Am 15:1177, 1995

REFERRING VET

Dr. Garb

INVOICE

24484

DATE

5/27/22



PATIENT

Lucky Martinez-Bauer

SPECIES

Canine

BREED

Min. Schnauzer Mix

SEX

Male Intact

AGE

8 years

WEIGHT

24.9lbs

INTERPRETED BY

Maggie Machen Lamy,
DVM, DACVIM
(Cardiology)

IMAGING PERFORMED BY

Dana Alterman,
RDCS, LVT

HOSPITAL NAME

Eubank Animal Clinic

REFERRING VET

Dr. Garb

INVOICE

24484

DATE

5/27/22

INTERPRETATION OF THE FINDINGS & FURTHER RECOMMENDATIONS

Chronic degenerative valve disease persists with evidence of progression. Previously mild disease has become moderate with moderate mitral and mild tricuspid regurgitation. The left atrial and ventricular dimensions have increased comparatively; however, there remains relatively low risk for imminent complication. Risk for progression to spontaneous congestive heart failure in the future is elevated. No additional issues are identified. The ECG is unremarkable with a normal sinus rhythm.

Given evidence of progression and results of the EPIC trial, Pimobendan is indicated in this patient as below. This is a slightly conservative approach. Assessment of progression in the future will help predict long term outcome, however prognosis is guarded at this stage (B2).

Omega fatty acid supplementation and mild salt restriction may also be of some long-term benefit. Monitor for development of a progressive cough, labored breathing, exercise intolerance or collapse episodes.

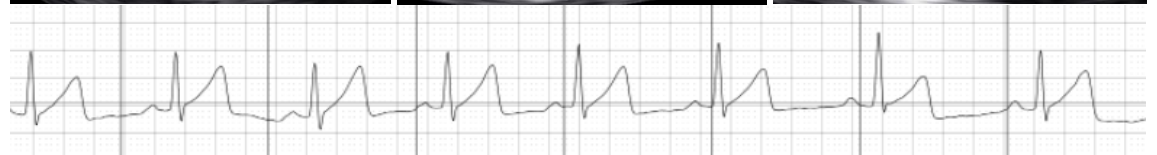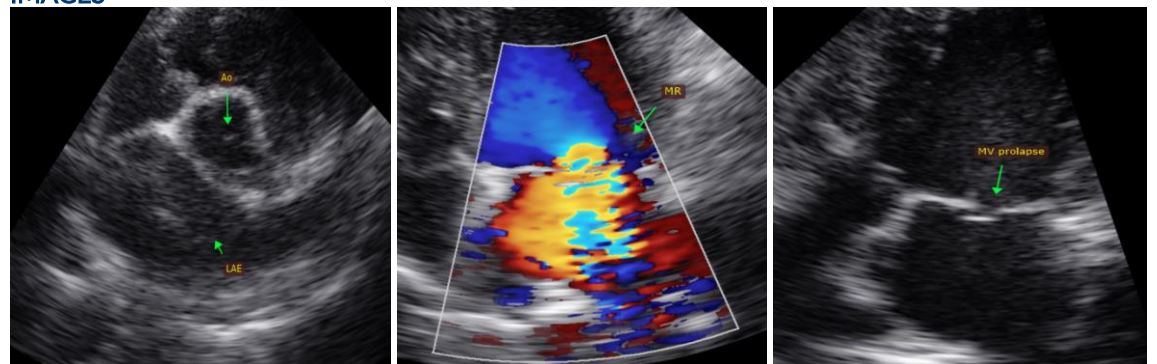
Once on the medication for 3-5 days, anesthetic risk is considered mildly elevated. Cardiac protective drug choices (opioid/benzodiazepine premedication, Propofol or alfaxalone induction, iso or sevo gas) are recommended. Monitor for arrhythmias, hypotension, and hypoxia both intra and post-operatively and intervene as necessary. Judicious IV fluid rates are recommended to avoid fluid overload. Avoid heart rate stimulating drugs such as atropine unless clinically indicated.

PLAN

Baseline BP recommended. Institute heart muscle support Pimobendan 0.25-0.3mg/kg PO q12h.

Recommend monitor for progression with a recheck echocardiogram in 6 months, sooner if any development of clinical signs.

IMAGES





PATIENT

Lucky Martinez-Bauer

The information and recommendations provided are based on the images presented by the referring veterinarian. No evaluation can be communicated regarding pathology that was not visible in the image/video clips provided.

SPECIES

Canine

Thank you for this referral. This report was generated using transcription software, and minor dictation errors may be present. If the clinical or image interpretation does not parallel your findings or if I can be of any further assistance, please contact me.

BREED

Min. Schnauzer Mix

Maggie Machen Lamy, DVM
Diplomate of the American College of Veterinary Internal Medicine (Cardiology)
info@sonopath.com

SEX

Male Intact

AGE

8 years

WEIGHT

24.9lbs

INTERPRETED BY

Maggie Machen Lamy,
DVM, DACVIM
(Cardiology)

**IMAGING
PERFORMED BY**

Dana Alterman,
RDCS, LVT

HOSPITAL NAME

Eubank Animal Clinic

REFERRING VET

Dr. Garb

INVOICE

24484

DATE

5/27/22